

Treatment with the Mandibular Arnold Expander

NEAL D. KRAVITZ, DMD, MS

Dental crowding—otherwise referred to as tooth-size/arch-length discrepancy (TSALD)—is the most common component of malocclusion among orthodontic patients. According to the National Center for Health Statistics, 40% of preadolescent children and 85% of adolescents exhibit TSALD.^{1,2} Particularly prevalent in the mandibular arch, it is often the determining factor in the decision whether to extract teeth.

Relief of crowding is more challenging in the lower arch than in the upper arch because of the absence of a midline suture and the resistance of the mandibular body. Any attempt to achieve substantial mandibular dental expansion with fixed appliances can result in undesirable incisor and canine proclination outside the supported bony housing, which can strain the periodontium, alter the occlusion, and increase the potential for relapse. Therefore, the pretreatment mandibular intercanine width has been considered an inviolable measurement.³⁻⁶

Moderate increases in mandibular intercanine width may be possible, however, if expansion is begun prior to the eruption of the permanent canines.^{7,8} This article describes the use of the Arnold expander*—also known as the expansion arch or E-arch—as a means of mandibular expansion in patients with moderate TSALD. Although the mandibular Arnold expander is most

commonly applied during early interceptive treatment, its use during late adolescence will also be discussed.

Appliance Design

The Arnold appliance is a fixed, coil-spring device that was popularized by Berkowitz in the 1970s as a way to produce slow, orthopedic maxillary expansion in cleft-palate patients.⁹ In the mandibular arch, the Arnold appliance can open 4-5mm of space through tipping of the buccal teeth and distalization of the first molars¹⁰ (Fig. 1).

The device has a split lingual frame—an .040" tube on one side and a wire insert on the other—connected by an .010" × .040" Elgiloy** or nickel titanium open-coil spring. Seating the appliance compresses the spring and activates it for expansion. Because there is no need to turn an expansion key or make any further adjustments, the Arnold appliance is ideal for anxious patients

*AOA Orthodontic Appliances, Sturtevant, WI; www.aolab.com.
**Registered trademark of Rocky Mountain Orthodontics, Denver, CO; www.rmortho.com.

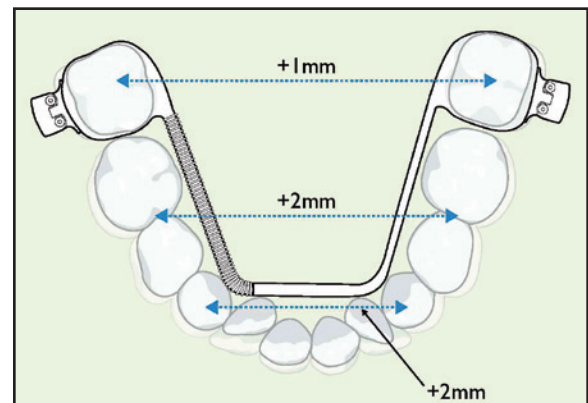


Fig. 1 Mandibular Arnold expander produces 4-5mm of transverse dental expansion, mostly in canine and premolar regions.

Dr. Kravitz is a Contributing Editor of the *Journal of Clinical Orthodontics*; an adjunct faculty member, Department of Orthodontics, Washington Hospital Center, Washington, DC; and in the private practice of orthodontics at 25055 Riding Plaza, Suite 110, South Riding, VA 20152; e-mail: nealkravitz@gmail.com.



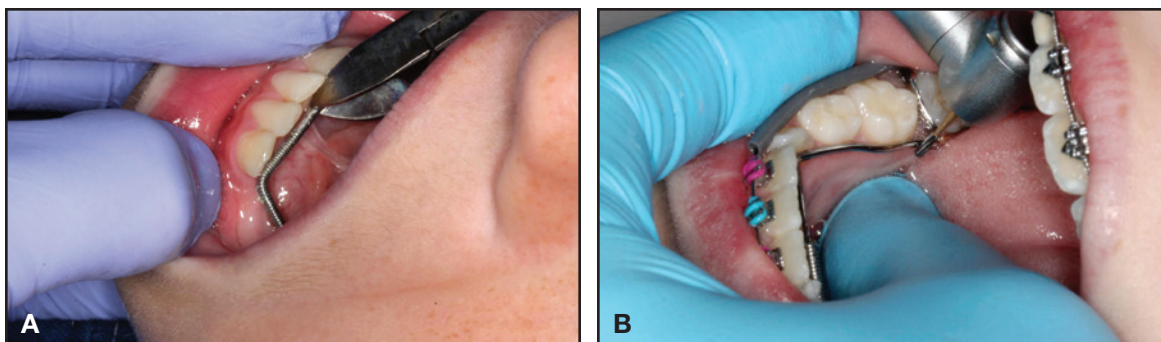


Fig. 2 A. Appliance deactivated by pinching tube firmly with heavy-wire cutter. (Alternative is to cut through open-coil spring, leaving frame intact.) **B.** Appliance removed by sectioning lingual frame mesial to first molar, using No. 557 crosscut-fissure carbide bur.

or when parental participation is a concern.

The distal arms of the expander are normally soldered to bands on the mandibular first permanent molars. If these teeth have not fully erupted, the appliance can be fitted to the second deciduous molars; in that case, the laboratory technician should be instructed to add lingual extension arms to the first permanent molars, allowing simultaneous expansion of the posterior teeth. Since I often use the Arnold expander in conjunction with full fixed appliances, I also ask the technician to keep buccal tubes on the molar bands. A mandibular 2 × 4 appliance with a continuous archwire can correct malocclusions associated with TSALD, including incisor rotations, deep overbite, anterior crossbite, and tooth impaction due to premature exfoliation of the mandibular deciduous canines.

Once the desired expansion has been achieved, the appliance is made passive in one of two ways: pinching the .040" tube firmly against the wire insert with a heavy-wire cutter (Fig. 2A) or cutting through the open-coil spring while keeping the frame intact. Either method essentially converts the appliance into a holding arch. The passive Arnold expander can be left in place until the eruption of the mandibular second premolars or the start of Phase II treatment. If the appliance causes pain by embedding in the lingual tissue, becomes covered with calculus, or impedes the eruption of a tooth, I remove the lingual frame by sectioning the expander mesial to the first mo-

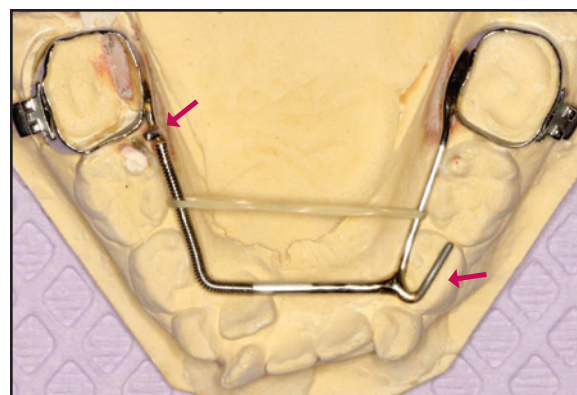


Fig. 3 Dr. James Thacker's variation on traditional mandibular Arnold expander, with deciduous-molar occlusal rest and mesial stop for open-coil spring (appliance fabricated by AOA Labs).

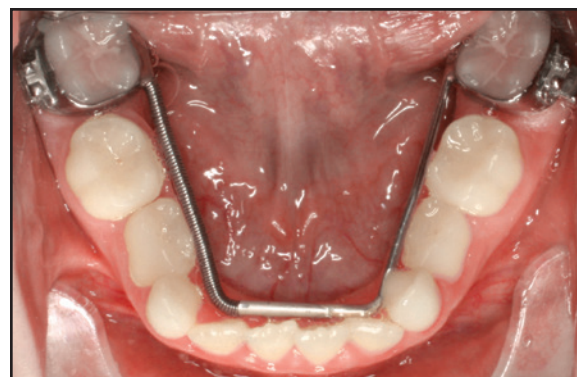

Fig. 4 Lingual frame of expander has lifted above occlusal table, resulting in molar distalization rather than transverse expansion.

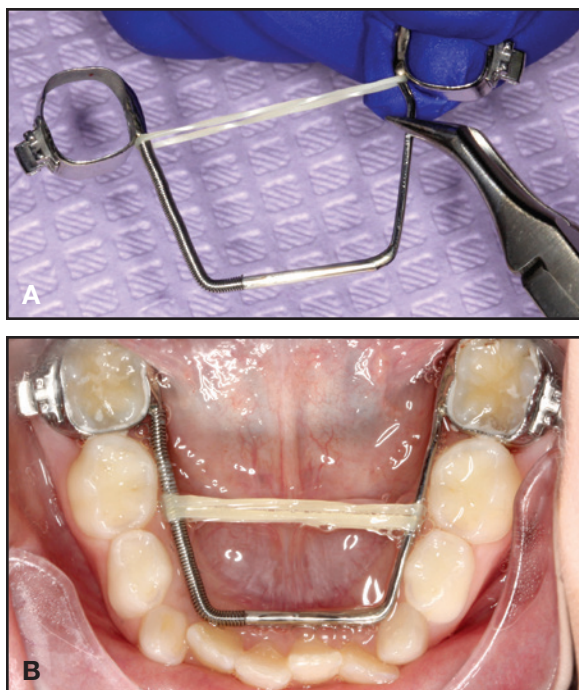


Fig. 5 A. Frame bent slightly downward with Weingart plier before appliance insertion. B. Frame inserted, with elastic holding two segments together.

lar with a No. 557 crosscut-fissure carbide bur (Fig. 2B).

An alternative developed by Dr. James Thacker incorporates two additional features: an occlusal rest for the first deciduous molar, on the side opposite the open-coil spring, and a stop for the spring (Fig. 3). Since some patients have a tendency to lift the lingual frame by pulling on it with their fingers or repeatedly flicking it with the tongue, the occlusal rest prevents the expander from rising above the occlusal table, where it might impede dental eruption and result in molar distalization rather than transverse dental expansion (Fig. 4). To prevent further lifting, the wire side of the frame can be bonded to the left deciduous canine with flowable composite. Securing the appliance on one side will not affect the symmetry of expansion, but will impede molar distalization on the bonded side. Placing the stop mesial to the first molar on the spring side of the appliance makes it

easier to section the lingual frame for removal, and it also keeps the spring from irritating the patient when the frame is cut.

Appliance Insertion and Activation

Before inserting the Arnold expander, wrap an orthodontic elastic around the lingual frame to compress the coil spring and keep the two sections of the appliance together. Holding the molar band with the fingers, bend the frame slightly downward with a Weingart plier to help prevent it from rising above the occlusal surface during expansion (Fig. 5A). Seat the appliance with the elastic still tightly wrapped around the lingual frame (Fig. 5B), then remove the elastic with a pin-and-ligature cutter.

The Arnold expander should be activated for nine to 12 months, depending on the severity of crowding. Most patients will also need a rapid maxillary expander (RME) in the upper arch; the Arnold appliance establishes a “reference” mandibular arch width to guide the maxillary expansion. Since the RME may need to be reactivated for arch coordination, I do not remove the expander or seal the expansion screw until satisfactory mandibular expansion has been achieved.

Case 1 (Preadolescent)

A 7½-year-old male presented with a Class I skeletal relationship. The patient displayed maxillomandibular transverse constriction, a 1mm overbite, severe crowding, an unerupted upper right central incisor, and impacted upper and lower lateral incisors (Fig. 6). He had been diagnosed with hemophilia A, which was being treated with desmopressin to stimulate the release of von Willebrand factor. In collaboration with his physician, we presented a plan for 18 months of Phase I treatment with a banded maxillary Hyrax-type RME and a removable mandibular Schwarz appliance, followed by anterior fixed appliances.

After three months of failed compliance with the Schwarz appliance, the parents opted for a fixed Arnold expander. Eight months later, the dental expansion had allowed complete eruption of the lower lateral incisors (Fig. 7). Due to the

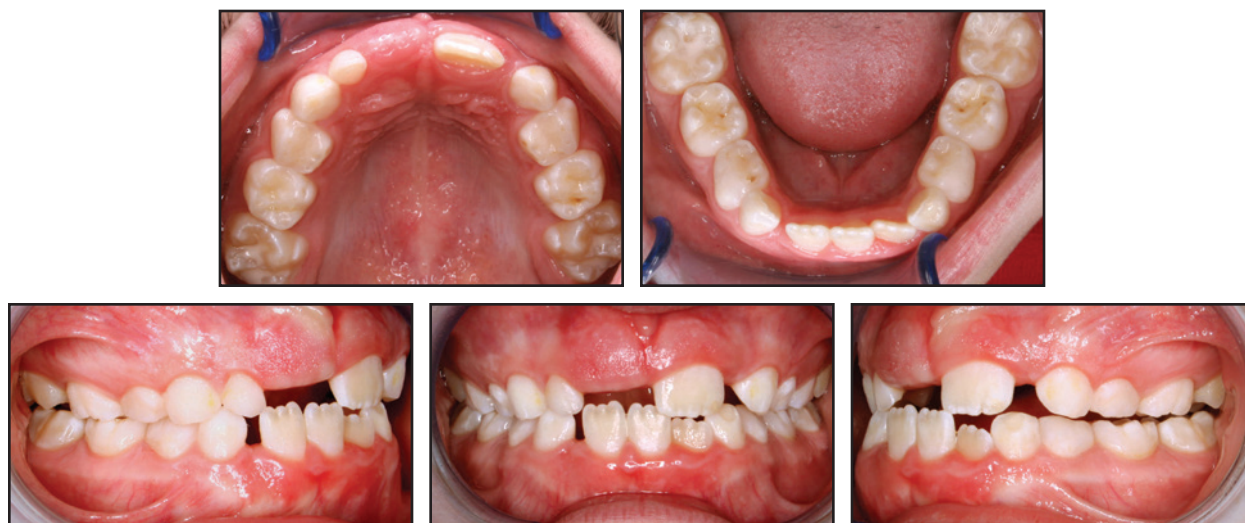

Fig. 6 Case 1. 7½-year-old male patient with upper and lower transverse constriction, Class I malocclusion with 1mm overbite, severe crowding, unerupted upper right central incisor, and impacted upper and lower lateral incisors before treatment.

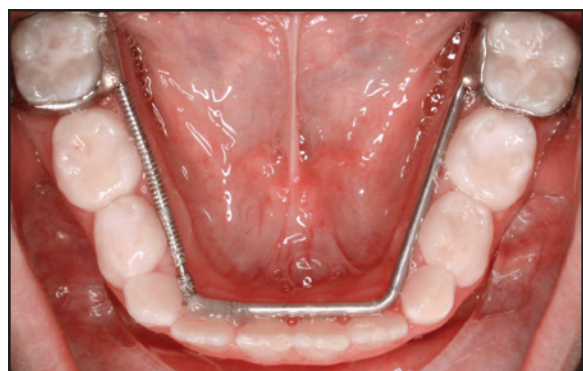

Fig. 7 Case 1. Mandibular Arnold appliance deactivated following expansion and complete eruption of mandibular lateral incisors.

severity of crowding in this case, the first molars were slightly overexpanded and tipped buccally. The appliance was then deactivated by drilling through the coil spring with a No. 557 crosscut-fissure carbide bur, converting the expander into a holding arch. Flowable composite was placed over the broken coil spring to prevent tongue irritation.

The lower lateral incisors erupted in proper alignment without being bracketed. All other fixed appliances were removed after 18 months of active treatment. A Phase I Hawley retainer with a 2-2 labial bow was prescribed for maxillary retention; the passive mandibular Arnold appliance was left

in place until the eruption of the lower second premolars (Fig. 8).

Case 2 (Late Adolescent)

A 14-year-old male presented with a Class I skeletal relationship. Clinical examination indicated excessive maxillary transverse arch width, bimaxillary dental protrusion, generalized spacing, a 2mm overbite, and a bilateral posterior buccal crossbite (Fig. 9). The patient's dental history included macroglossia and a forward tongue thrust. Because the parents preferred a nonsurgical, non-extraction approach, the treatment plan called for comprehensive orthodontic therapy, with a reverse-turn maxillary Hyrax-type RME and a mandibular Arnold expander used to correct the buccal crossbite, followed by full fixed appliances to consolidate spacing and reduce the dental protrusion.

Unlike the conventional RME, the reverse-turn RME is flipped and expanded prior to placement; otherwise, the parent would have to turn the expander from back to front, which can be challenging. A traditional four-arm screw is used instead of a ratchet-type two-arm screw to allow backward turning. Premolar bands are incorporated for maxillary dental constriction; in addition, buccal bars may be soldered between the first-premolar and first-molar bands to control constrict-

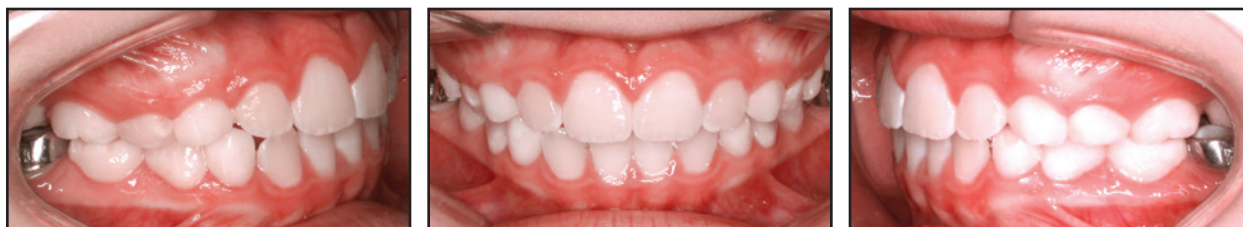

Fig. 8 Case 1. Patient after 18 months of Phase I treatment.

tion of the second premolars. In this case, the reverse-turn RME was constricted .5-.75mm per week (one turn of the expander every two or three days) for 12 weeks (Fig. 10A).

The mandibular Arnold expander was inserted at the same appointment as the reverse-turn RME (Fig. 10B). After three months of simultaneous maxillary dental constriction and mandibular dental expansion, the buccal crossbite had been corrected (Fig. 11). Both appliances were then sectioned, and full-arch .018" appliances were bonded. Treatment was completed in 16 months (Fig. 12). Fixed maxillary and mandibular lingual retainer wires*** were bonded, and circumferential Hawley-type overlay retainers were also provided.

It can be challenging to correct a buccal crossbite with fixed appliances, since the lingual cusps of the upper teeth tend to debond the lower posterior brackets, requiring the lower premolars and molars to be banded. In this patient, the mandibular Arnold expander allowed more expeditious correction of the bilateral buccal crossbite than if a reverse-turn RME had been used alone; it also reduced the amount of maxillary dental constriction that was needed.

Discussion

The etiology of TSALD has been attributed to multiple factors.^{11,12} Hereditary causes include excessive tooth size, deficient arch length, narrow arch width, supernumerary or missing teeth, and abnormal crown morphology. Environmental influences include premature loss of deciduous teeth, interproximal caries, transpositions or disturbances in dental eruption, muscle imbalance, and even socioeconomic conditions. Some of these environmental factors may be related to an evolu-

***Ortho-Flextech, Reliance Orthodontic Products, Itasca, IL; www.relianceorthodontics.com.

tionary reduction in interproximal tooth wear caused by a decreasing human jaw size and a diet of softer foods.¹¹

A developing TSALD can be detected as early as age 2, after the completion of the primary dentition. Insufficient spacing of the smaller anterior deciduous teeth, referred to as a "closed" primary dentition, is often the first indicator of moderate-to-severe TSALD in the permanent dentition. This "incisor liability" (the size differential between the deciduous and permanent incisors) inhibits an "early mesial shift" (forward migration of the erupting mandibular first permanent molars into a Class I relationship) by closing the spaces distal to the deciduous canines.

In the early mixed dentition, around age 7-9, clinical signs of a TSALD may include bimaxillary protrusion without interproximal spacing, overlapping or winged incisors, and, most significant, premature exfoliation of the mandibular deciduous canines. The mandibular permanent canines should normally erupt between ages 9½ and 10. Early loss of a single deciduous canine will result in a midline shift to the affected side, and early loss of both canines will cause lingual migration of the mandibular incisors due to muscle pressure from the lower lip. Lingually positioned mandibular incisors will impede eruption of the mandibular permanent canines, requiring serial extractions.

According to McNamara, TSALD patients can be divided into three categories, based on the amount of mandibular crowding¹³:

1. Clear-cut nonextraction cases (less than 3mm of mandibular crowding).
2. Clear-cut extraction cases (more than 6mm of mandibular crowding).
3. Borderline crowding cases (3-6mm of mandibular crowding).

In a borderline patient, the decision whether

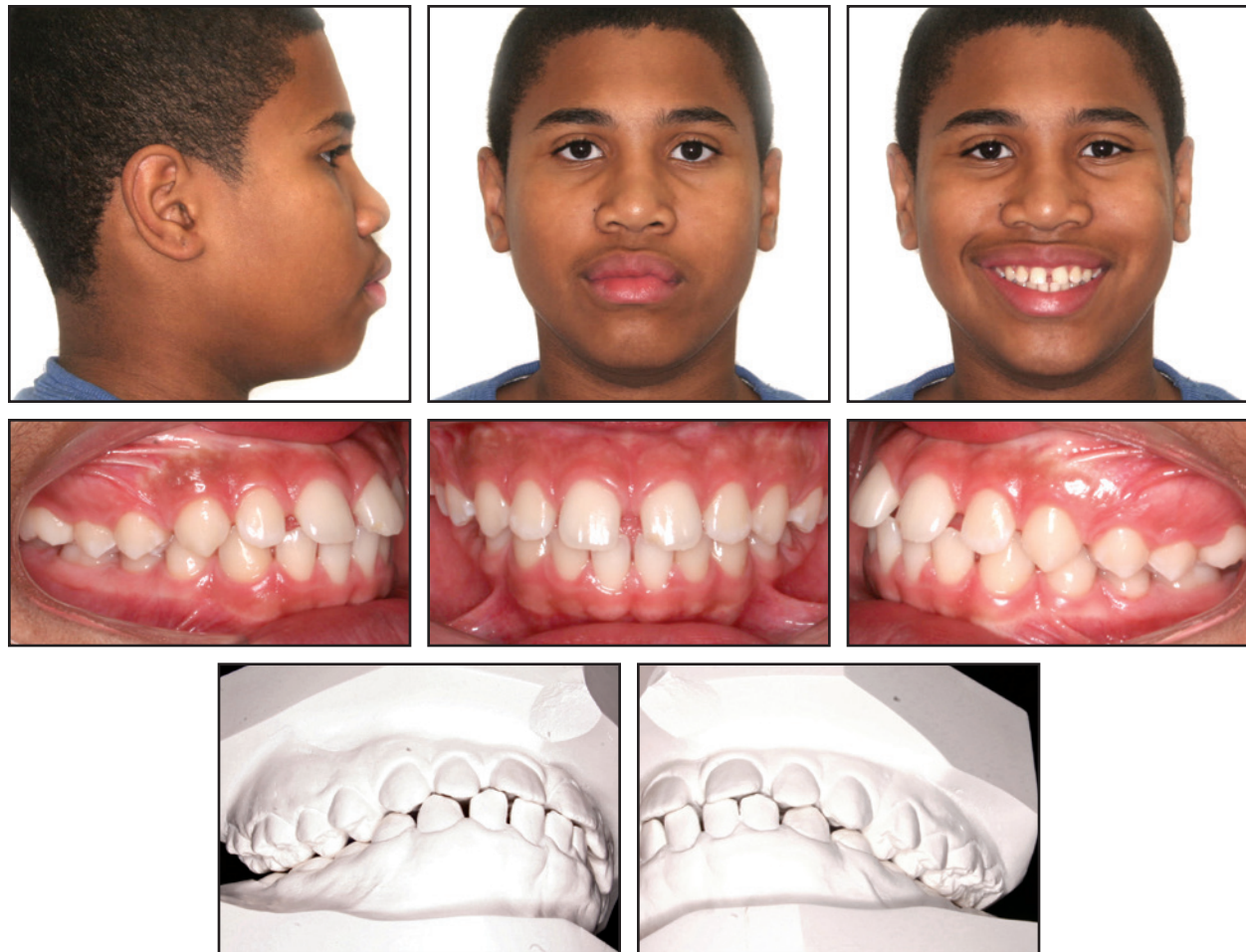


Fig. 9 Case 2. 14-year-old male with excessive maxillary transverse width, Class I malocclusion with bi-maxillary dental protrusion, generalized spacing, 2mm overbite, and bilateral posterior buccal crossbite before treatment.

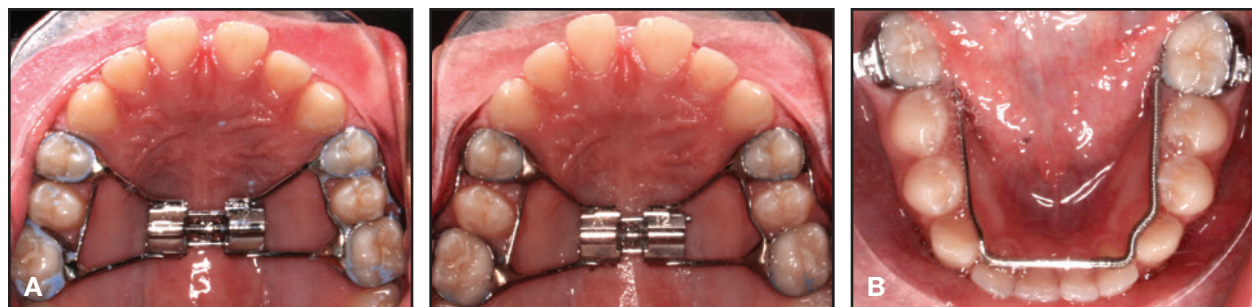

Fig. 10 Case 2. A. Maxillary constriction before and after three months of treatment with reverse-turn rapid maxillary expander. Buccal bars soldered between first premolars and first molars control constriction of second premolars. B. Insertion of mandibular Arnold appliance.

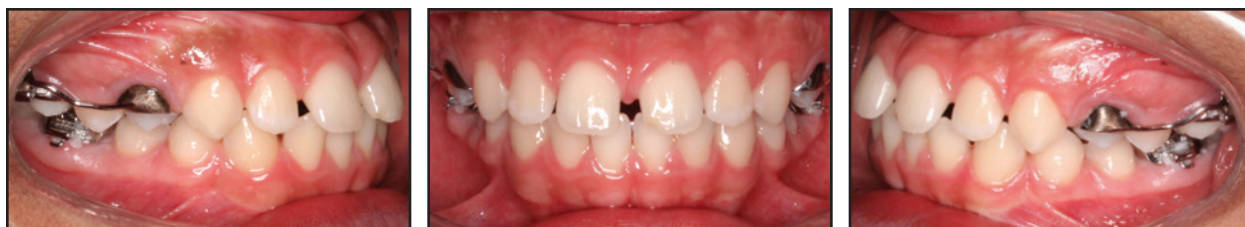

Fig. 11 Case 2. Correction of bilateral buccal crossbite in three months.

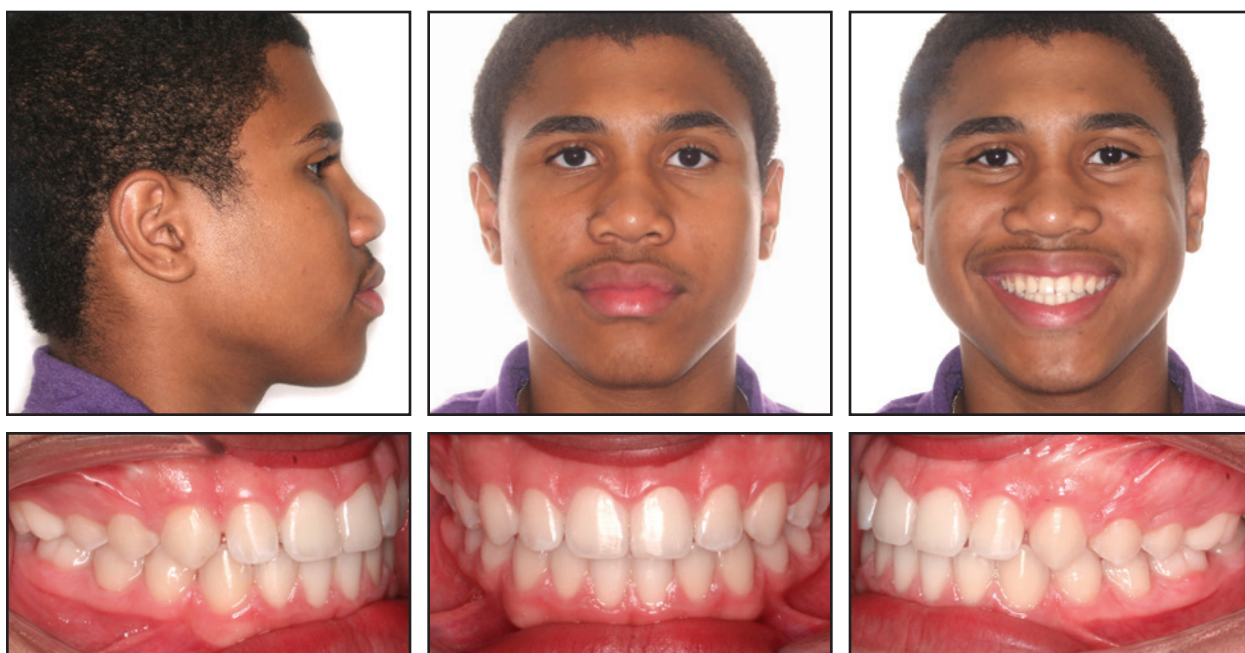

Fig. 12 Case 2. Patient after 16 months of treatment.

to regain space with mandibular expansion or proceed with serial extractions is a difficult one, often depending on secondary factors such as age, bio-type, thickness of the dentoalveolus, tooth inclinations, impactions, soft-tissue esthetics, patient concerns, preferences of the referring dentist, and even the need for treatment of the maxillary arch.

In fact, the maxillary skeletal morphology has a significant influence on a TSALD in the mandibular dentition. When the maxillary apical base is widened by rapid palatal expansion, the buccinator muscles move away from the mandibular dentition and the tongue moves away from the throat and up toward the roof of the mouth,

producing a concomitant increase in mandibular arch width.¹⁴ Lima and colleagues reported that 8-11mm of maxillary expansion produced about 1mm of spontaneous mandibular intermolar expansion in patients treated during the late mixed dentition.¹⁵ Similarly, O'Grady and colleagues found that 8mm of maxillary expansion produced approximately 2mm of spontaneous mandibular expansion in patients treated in the early mixed dentition, prior to the eruption of the mandibular permanent canines.¹⁶ This spontaneous mandibular expansion seems to affect intermolar width more than intercanine width. Thus, in patients with severe mandibular anterior crowding, an

RME may provide space in the lower arch, but not where it is needed most.

In a retrospective study of the Arnold expander in the late mixed dentition, Housley and colleagues reported mean increases of 2mm in the mandibular intercanine and interpremolar widths.¹⁷ Intermolar arch width increased by only 1mm—the same as spontaneous mandibular expansion following rapid maxillary expansion. In other words, the effects of the Arnold expander, when used in conjunction with an RME, appear limited to the mandibular canine and premolar regions.

Maxillary expansion has been shown to facilitate mandibular expansion, but the reverse is also true. O'Grady and colleagues found that combining rapid maxillary expansion with mandibular expansion led to significantly greater long-term increases in maxillary arch perimeter than were achieved using an RME alone.¹⁶ By uprighting the mandibular posterior teeth, mandibular expansion enabled a greater amount of maxillary expansion that was also more stable over time. In our office, although an Arnold expander is not used in every preadolescent patient who requires maxillary expansion, almost every patient who receives an Arnold expander also receives an RME.

The Arnold expander does have limitations that should be considered. Housley and colleagues reported that interarch expansion in the canine-premolar region declined by about 50% in the absence of fixed retention.¹⁷ Moreover, prolonged mandibular dental expansion may result in excessive buccal tipping of the posterior teeth. Failure to deactivate the appliance at the appropriate time can cause the two halves of the lingual frame to separate. In rare instances, a patient with a high lingual frenum or “tongue tie” may develop an aphthous ulceration or minor tearing of the frenal attachment due to rubbing from the lingual frame.

Conclusion

The Arnold expander produces 4-5mm of mandibular dental expansion without the need for patient compliance. It is indicated primarily in mixed-dentition patients with moderate TSALD as a means of temporary space gain, allowing erup-

tion of the permanent teeth, but it can also be applied in older patients for the correction of buccal crossbites. Regardless of age, mandibular expansion can be preserved only by fixed retention. The amount of crowding that can be resolved with stable dental expansion should be carefully considered when deciding whether to expand or extract.

REFERENCES

1. Kelly, J.E.; Sanchez, M.; and Van Kirk, L.E.: An assessment of the occlusion of teeth of children 6-11 years, *Vital Health Stat.* 130:1-60, 1973.
2. Kelly, J.E. and Harvey, C.R.: An assessment of the occlusion of teeth of youths 12-17 years, *Vital Health Stat.* 162:1-65, 1977.
3. Riedel, R.: Review of the retention problem, *Angle Orthod.* 6:179-199, 1960.
4. Little, R.M.; Riedel, R.A.; and Stein, A.: Mandibular arch length increase during the mixed dentition: Postretention evaluation of stability and relapse, *Am. J. Orthod.* 97:393-404, 1990.
5. Strang, R.H.W.: The fallacy of denture expansion as a treatment procedure, *Angle Orthod.* 19:12-22, 1949.
6. Schulhof, R.J.; Lestrel, P.E.; Walters, R.; and Schuler, R.: The mandibular dental arch, Part 3: Buccal expansion, *Angle Orthod.* 48:303-310, 1978.
7. Cetlin, N.M. and Ten Hoeve, A.: Nonextraction treatment, *J. Clin. Orthod.* 17:396-413, 1983.
8. Osborn, W.S.; Nanda, R.S.; and Currier, G.F.: Mandibular arch perimeter changes with lip bumper treatment, *Am. J. Orthod.* 99:527-532, 1991.
9. Berkowitz, S.: Complete bilateral cleft of the lip and palate, in *Cleft Lip and Palate: Diagnosis and Management*, 3rd ed., ed. S. Berkowitz, Springer, New York, 2013, p. 177.
10. Kravitz, N.: The mandibular E-arch: A noncompliant alternative to Phase I mandibular expansion, *Orthod. Prod.*, March 2009, pp. 26-28.
11. Ngan, P.; Alkire, R.G.; and Fields, H. Jr.: Management of space problems in the primary and mixed dentitions, *J. Am. Dent. Assoc.* 130:1330-1339, 1999.
12. Dale, J.G.: Guidance of occlusion: Serial extraction, in *Orthodontics: Current Principles and Techniques*, ed. T.M. Graber and B.F. Swain, Mosby, St. Louis, 1985, pp. 259-366.
13. McNamara, J.A. Jr.: Early intervention in the transverse dimension: Is it worth the effort? *Am. J. Orthod.* 121:572-574, 2002.
14. Haas, A.J.: Rapid expansion of the maxillary dental arch and nasal cavity by opening the midpalatal suture, *Angle Orthod.* 31:73-90, 1961.
15. Lima, A.C.; Lima, A.L.; Filho, R.M.; and Oyen, O.J.: Spontaneous mandibular arch response after rapid palatal expansion: A long-term study on Class I malocclusion, *Am. J. Orthod.* 126:576-582, 2004.
16. O'Grady, P.W.; McNamara, J.A. Jr.; Baccetti, T.; and Franchi, L.: A long-term evaluation of the mandibular Schwarz appliance and the acrylic splint expander in the early mixed dentition patients, *Am. J. Orthod.* 130:202-213, 2006.
17. Housley, J.A.; Nanda, R.S.; Currier, G.F.; and McCune, D.E.: Stability of transverse expansion in the mandibular arch, *Am. J. Orthod.* 124:288-293, 2003.